

*"packer in asbestos"*

## A CASE OF OAT CELL CARCINOMA OF THE LUNG OCCURRING IN ASBESTOSIS.

By S. ROODHOUSE GLOYNE, M.D., D.P.H.

*Pathologist, City of London Hospital for Diseases of the Heart and Lungs, Victoria Park.*

A YEAR ago the writer published a short note [1] on the occurrence of squamous carcinoma in two cases of pulmonary asbestosis. The following case in which the asbestosis was accompanied by an oat cell carcinoma of the lung appears to be worth recording in view of the pathological differences between the two types of cases.

### CLINICAL AND OCCUPATIONAL HISTORY.

The patient, A. C. G., was a male aged 59. He began work as a packer in an asbestos works in 1912 and eighteen months later was promoted to be a foreman in the stores department. He remained at work and apparently quite well until March, 1933, when he began to complain of pains in the chest and abdomen and he died in September of the same year.

### AUTOPSY.

At the post-mortem examination both lungs showed extensive asbestosis of typical distribution with horny thickening of the visceral pleura over both lower lobes. In the left lower lobe there was a neoplasm about the size of a golf ball in the peripheral portion of the lobe and extending in some places to the pleura with which it appeared to be continuous. The growth was pinkish-white in colour, soft in texture and fairly well marked off from the surrounding lung tissue. Over the growth the pleura was umbilicated. At the apex of the left upper lobe there was also a small mottled area of growth, extending to the pleura. The mediastinal lymph glands were small and pigmented and showed no naked eye signs of growth. There were no secondary deposits in other organs.

### HISTOLOGY.

Microscopically the growth was found entirely to replace lung tissue. The cells were small round cells and small spindle cells arranged in solid columns between strands of connective tissue. In places these two types of cell appeared to be irregularly assorted without any arrangement. In other places the spindle cells almost alone formed the columns. In yet other parts they occupied the external portions of the columns which consisted of an internal core of small round cells. Probably these different appearances are due to the various angles at which the columns were cut. The nuclei of both round and oat cells were small and compact, and a chromatin network was difficult to define. Nucleoli were not recognised and mitotic figures were not found. Lying free here and there in the columns of cells were large vacuolated macrophages containing pigment, the remains of the macrophages found in pulmonary alveoli. Asbestosis bodies occurred singly and in small clumps indiscriminately arranged, but were not numerous. The growth was sharply separated from the surrounding asbestotic lung by the collagenous connective tissues




FIG. 1.—Photomicrograph of oat cell carcinoma in asbestosis. (x 600).

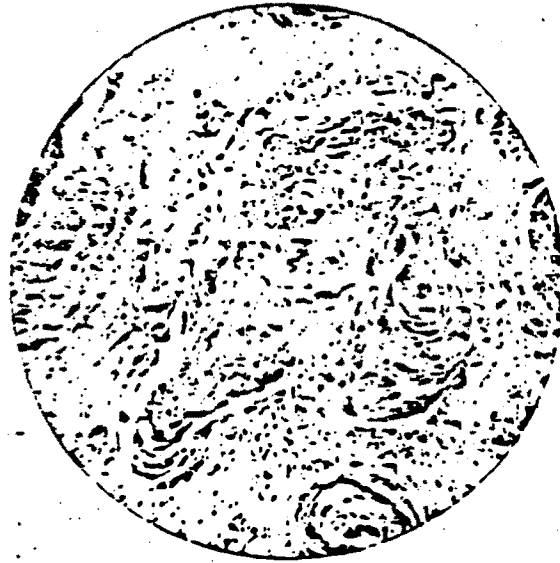


FIG. 2.—Photomicrograph of squamous cell carcinoma. (x 150).

To illustrate article, "A Case of Oat Cell Carcinoma of the Lung Occurring in Asbestosis,"  
by S. ROBINSON GLOVE, M.D., D.P.H.

of the latter and there was practically no sign of any infiltration, so that it was possible to say definitely where growth began and ended.

#### COMMENTS.

Comparing this oat cell type of growth with the squamous cell type already recorded as a complication of pulmonary asbestosis a difference in the manner of extension is noted. The squamous type advanced by a continuous prolongation of finger-like processes along the mucosa of the small bronchi; the oat cell type grew outwards from a centre in a compact mass destroying lung tissue as it progressed and showed no tendency to confine itself to prolongation along and infiltration of the bronchial mucosa.

#### REFERENCE.

- [1] GLOYNE, S. R. *Tubercle*, 1935, 17, 5.

### THE INTRA-DERMAL TUBERCULIN TEST IN NURSES.

By PETER W. EDWARDS, M.B., B.Ch. Edin.

*Medical Superintendent, Cheshire Joint Sanatorium, Market Drayton, and Wrenbury Hall Colony, Nantwich.*

THE following is an interim record of a short series of intra-dermal tuberculin tests on nurses at this sanatorium. The cases have not been followed up since leaving the institution.

Fifty-four were Mantoux positive on joining the staff, of whom one became tuberculous in six months.

Eleven were Mantoux negative on joining the staff. Of these: Two left after the first test; one is negative on third test after four months; one is negative on third test after three months; one is negative on second test after two months (these nurses all appear fit and are still being tested); one became positive a month later and was then tuberculous (i.e. tuberculous within two months); one became doubtful in one month and positive on the third test the following month, and was then tuberculous (i.e. tuberculous within three months); one became positive on third test three months later (appears fit); one became positive on second test eight months later (she appears quite fit); two became positive on second test ten months later (they appear quite fit).

This small series of figures appears to support Heimbeck's findings in Oslo.

It may be of interest to add that 43 female domestics have been tuberculin tested since 1933: 40 were Mantoux positive on admission and as far as I know remained free from tuberculosis. Three were Mantoux negative: of these one left after the first test; one is still negative after the third test ten months later (these two are quite fit); one is positive on second test a month later (she appears fit).

Of the male outdoor staff, we have only Mantoux-tested six. Five were positive on admission and are fit. One was negative on admission and remained negative after the third test four months later and appears fit.